

Fatty Liver Automatic Diagnosis from Ultrasound Images

Ricardo Ribeiro^{1,2}, José Seabra² and João Sanches^{2,3}

¹Escola Superior de Tecnologia da Saúde de Lisboa, ²Instituto de Sistemas e Robótica, ³Instituto Superior Técnico
Lisboa, Portugal
(ricardo.ribeiro@estesl.ipl.pt, jseabra@isr.ist.utl.pt and jmsr@ist.utl.pt)

Abstract

In this paper an automatic classification algorithm is proposed for the diagnosis of the liver steatosis, also known as, fatty liver, from ultrasound images.

The features, automatically extracted from the ultrasound images used by the classifier, are basically the ones used by the physicians in the diagnosis of the disease based on visual inspection of the ultrasound images.

The main novelty of the method is the utilization of the speckle noise that corrupts the ultrasound images to compute textural features of the liver parenchyma relevant for the diagnosis.

The algorithm uses the Bayesian framework to compute a noiseless image, containing anatomic and echogenic information of the liver and a second image containing only the speckle noise used to compute the textural features.

The classification results, with the Bayes classifier using manually classified data as ground truth show that the automatic classifier reaches an accuracy of 95% and a 100% of sensitivity.

1. Introduction

The liver has a limited repertoire in response to injury. Fatty liver is the initial and most common histologic response to hepatotoxic stimuli, including excessive alcohol ingestion [1]. It can also be associated with obesity, diabetes mellitus, oral contraceptives, severe hepatitis and idiopathic. It occurs when the fat content of the hepatocytes increases [2].

Ultrasound (US) is the preferred image modality in the diagnosis of diffuse liver diseases but it is highly subjective and operator-dependent [3,4,5]. Therefore, a highly experimented operator is needed to detect subtle changes on the hepatic texture.

The purpose of this work is to design and implement an automatic classifier to detect the steatotic disease from ultrasound images of the liver parenchyma, based on the traditional criteria used by the physicians in the diagnostic process based on visual inspection of the ultrasound images (see Fig. 1).

The method uses a Bayes classifier that combines intensity and textural features in the classification

process. A Bayesian framework is used to compute a noiseless image, containing anatomic and echogenic information of the liver parenchyma and an image containing only the speckle noise used to compute the textural features, according Fig. 2.

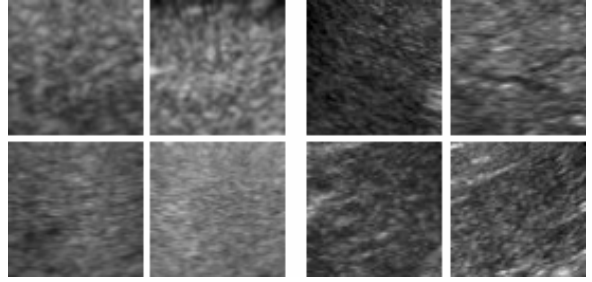


Figure 1. Liver tissues samples: Steatosis (two left rows) and Normal (two right rows)

2. Problem Formulation

The first step is the pre-processing of the ultrasound images to estimate the original radiofrequency, RF, signal, by using the method proposed in [6]. From this image the original noiseless anatomic information is computed using the method proposed in [7] as well as the textural information encoded in the speckle noise.

The speckle noise is obtained from the RF, $rf(i, j)$, and noiseless image, $f(i, j)$ through

$$Tx(i, j) = rf(i, j) / \sqrt{f(i, j)}$$

where it was assumed a Rayleigh distribution for $rf(i, j)$ which correspond to a multiplicative model for the speckle noise generation process.

The noiseless image $f(i, j)$ is computed in a Bayesian framework, formulated as a convex optimization task, where the observations are modeled by a Rayleigh distribution and the prior distribution is a Gibbs distribution with edge preserving Log-Total variation potential functions [7].

Diffuse fatty infiltration disease classification based on US images is usually based on two main features: increase in liver echogenicity and the decrease on the acoustic penetration, with loss or no visualization of the diaphragm and hepatic vessels [2].

Supported by these visual features, the pixel intensity decay *slope* in depth (from the de-noised image) is extracted from the noiseless image, $f(i, j)$,

using the least square method, by assuming that this is a linear decay.

From the textural image containing the speckle noise, $Tx(i, j)$, the first decomposition scale vertical, (EdV), and horizontal, (EdH) Haar wavelet detail energies are computed, to catch the diffuse characteristic of the fatty liver.

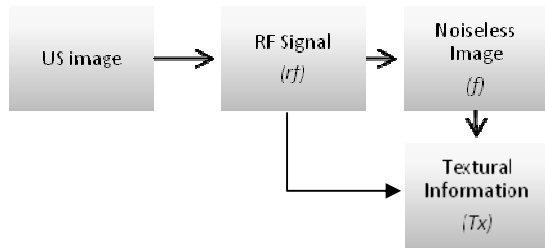


Figure 2. Pre-processing

In the present work we use a supervised learning system. As [8,9], we assume that feature vectors for normal and steatosis tissue have approximately normal distribution. A Binomial Bayesian classifier was built. The recognition system is operated in two modes: training (learning) and classification. For each texture class, 1=steatotic class and 2=normal class, the mean and covariance were estimated using the 20 images with the leave-one-out cross-validation method.

In this work 20 liver ultrasound images were obtained from 10 patients (5 with fatty livers and 5 with normal livers). The classification was made manually by radiologists and complementary indicators were obtained from laboratorial analysis.

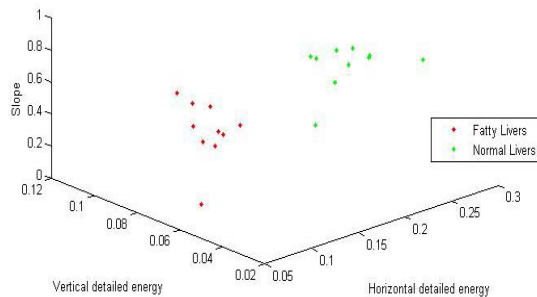


Figure 2 - Distribution of fatty vs Normal livers according the selected features

3. Experimental Results

As we can see from Fig. 3, the results have shown the usefulness of the features in the detection of pathological cases because almost no overlapping is observed between both statistical clouds.

Normal livers showed the following results: Slope ($\mu=0.8014$; $\sigma^2=0.0113$); EdH ($\mu= 0.1997$; $\sigma^2=0.0021$); EdV ($\mu=0.0466$; $\sigma^2=2.6068e-04$); and Fatty

livers: Slope ($\mu=0.4796$; $\sigma^2=0.0337$); EdH ($\mu=0.0979$; $\sigma^2=7.1793e-04$); EdV ($\mu=0.0678$; $\sigma^2= 2.6477e-04$).

The classification results have shown an overall accuracy of 95% with 100% of sensitivity, which is extremely important, since it is the conditional probability of detecting a disease while there is in fact a liver disease.

4. Conclusions

The proposed algorithm, based on the quantification of the visual diagnostic criteria, produces an objective analysis of the liver condition, which could be helpful to aid the diagnosis in this type of diffuse liver disease. Feature extraction from this algorithm allows a quantification of the visual diagnostic criteria.

A new objective criterion for feature extraction for the classification of this type of diffuse liver disease was proposed based on the visual diagnostic criteria.

Further studies in this area are needed. Other classification methods, such as neural network and the support vector machine classifiers should be tested, to optimize the process. Perform the feature extraction methods in the original US images, prior to machine processing.

4. Acknowledgement

This work was supported by Fundação para a Ciência e a Tecnologia (ISR/IST plurianual funding) through the POS Conhecimento Program which includes FEDER funds.

5. References

- [1] A. Fauci et al. *Harrison's Principles of Internal Medicine, 17th Edition*, The McGraw-Hill Companies, USA, 2008
- [2] V. Droga, D. Rubens. *Ultrasound Secrets*, Hanley and Belfus medical publishers, UK, 2004.
- [3] Y. Kono, R. Mattrey. Ultrasound of the liver. *Radiol Clin N Am*, 43:815 – 826, 2005.
- [4] S. Hussain, R. Semelka. Hepatic imaging: Comparison of modalities. *Radiol Clin N Am*, 43:929 – 947, 2005.
- [5] Y. Kadah et al. Classification Algorithms for quantitative tissue characterization diffuse liver disease from ultrasound images. *IEEE Trans Med Imaging*, 15:466-478, 1996.
- [6] J. Seabra, J. Sanches. Modeling Log-Compressed Ultrasound Images for Radio Frequency Signal Recovery, in *IEEE EMBC'08*, August 20-24, 2008.
- [7] J. Seabra, J. Xavier, J. Sanches. Convex Ultrasound Image Reconstruction with Log-Euclidean Priors. in *IEEE EMBC'08*, August 20-24, 2008.
- [8] W. Yeh et al. Liver fibrosis grade classification with b-mode ultrasound. *Ultrasound in Med. & Biol.* 29:1229–1235, 2003.
- [9] A. Mojsilovic et al. Characterization of visually diffuse diseases from b-scan liver images using non-separable wavelet transform. *IEEE Trans Med Imaging*, 17:541-549, 1999.